

SHARP

July 16, 2024

Patient: [REDACTED]

Date of Birth: **3/26/1975**

Date of Visit: **7/16/2024**

To Whom It May Concern:

[REDACTED] was diagnosed with idiopathic scoliosis.

If you have any questions or concerns, please don't hesitate to call.

Sincerely,



Jennifer Golden, DO

3:18

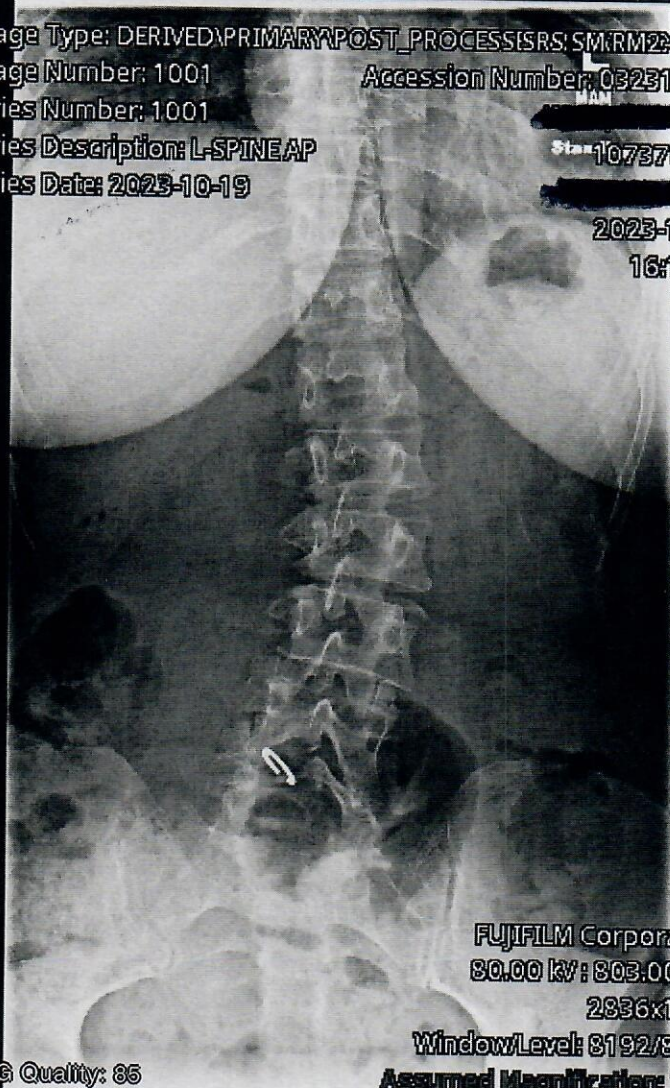
Sharp

53



Image Type: DERIVED\PRIMARY\POST_PROCESS\RS: SMRM2:10414
 Image Number: 1001 Accession Number: 03231990...
 Series Number: 1001
 Series Description: L-SPINE AP
 Series Date: 2023-10-19

Star 107378215
 : F
 2023-10-19
 16:10:53



cm
 CR
 FUJIFILM Corporation
 80.00 kV: 803.00 mA
 2836x1752
 Window Level: 8192/8192
 Assumed Magnification: 1.00

JPEG Quality: 85



AA emobility.sharp.com



3:15

Signal strength, Wi-Fi, and 5G icons

Back

P Test Details

Close

Report

LUMBAR SPINE, 3 VIEWS

The vertebral bodies are normal in height. The 12th ribs are hypoplastic. There is mild curvature to the left centered at L3. There is minimal spondylosis at L2-3. There is asymmetric right-sided disc space narrowing at L2-3.. There is no fracture or spondylolisthesis. The disc spaces are maintained.

IMPRESSION:

Scoliosis.

Asymmetric right-sided disc space narrowing at L2-3.

This exam was performed at: Sharp Rees-Stealy Sorrento Mesa

***** Final *****

Dictated by: Goodman MD, Eric T

Signed (Electronic Signature):

03/13/2019 10:48 am

Signed by: Goodman MD, Eric T

